



PATIENT

Buddy Dhillon

SPECIES

Canine

BREED

Goldendoodle

SEX

MN

AGE

16yr

WEIGHT

16kg

INTERPRETED BY

R. McKenzie Daniel,
DVM, DABVP
(Canine and Feline)

IMAGING PERFORMED BY

Dr Sarah Barthelemy

HOSPITAL NAME

Aspen Animal Hospital

REFERRING VET

Dr Ross

INVOICE 23085

DATE
12/01/2025

PRESENTING CLINICAL SIGNS

Recheck AUS to monitor previously noted spleen, liver and kidney changes.

ULTRASONOGRAPHIC EXAMINATION OF THE ABDOMEN

Urinary System

The urinary bladder, trigone, cystourethral junction, and visible pelvic urethra exhibited normal thickness and tone. Anechoic urine was present in the lumen with no evidence of urine/lumen sediment, mineral, or calculi. The ureteral papillae were normal. The ureters were not visible which is normal. No evidence of inflammatory or neoplastic changes was noted.

Normal size and margination were present in the kidneys. A normal 1:3 cortex / medulla ratio was maintained. The medulla and cortices were uniform in texture with some increased echogenicity and moderate loss of corticomedullary symmetry and definition expected for the age of the patient. Mild bilateral pyelectasia was present. The left kidney measured 5.2 cm in length. The right kidney measured 4.5 cm in length.

The area of the aortic trifurcation was free of pathology.

The residual prostate appeared normal and free of pathology

Adrenal Glands

The left adrenal gland was subnormal in size. The right adrenal gland exhibited mildly enlarged cranial pole. Mild parenchyma heterogeneity and mild capsule asymmetry was present without suspicion for overt neoplasia. The left adrenal gland measured 0.29 cm width in the caudal pole. The right adrenal gland measured 1.1 cm width in the cranial pole and 0.51 cm width in the caudal pole.

Spleen

Previously noted mildly progressive irregular mixed echogenic splenic mass was present measuring ~ 5.3 cm in diameter. The remainder of the spleen exhibited potential for mild generalized splenomegaly, maintained symmetrical capsule contour with mild heterogeneous parenchyma.

Liver/Gallbladder

The liver was subjectively normal in size, structure, and contour. The liver parenchyma was mildly nonuniform and hypoechoic to the spleen with a moderate coarse echotexture and subjective mild to benign parenchymal remodeling. A well demarcated non-homogenous hyperechoic intraparenchymal nodule was present in the deep mid liver measuring 1.4 cm in diameter. Normal vascular volume. The hepatic and portal vasculature were normal in appearance without signs of congestion. The gallbladder was non-distended in size with thin walls and non-organized hyperechoic debris. The cystic and common bile ducts were normal.

Gastrointestinal

The stomach presented intact wall layering with a normal wall layer ratio. The lumen of the stomach contained mild non-shadowing chyme and no signs of ileus, obstruction or foreign material.

The small intestine presented intact wall layering with 1:3 muscularis/mucosa ratio. The lumen of the small intestine was empty with no signs of mechanical/metabolic ileus, obstruction or foreign material. Intact subjective mildly thickened ileocolic wall was present measuring 0.57 cm in width.



PATIENT

Buddy Dhillon

SPECIES

Canine

BREED

Goldendoodle

SEX

MN

AGE

16yr

WEIGHT

16kg

INTERPRETED BY

R. McKenzie Daniel,
DVM, DABVP
(Canine and Feline)

IMAGING PERFORMED BY

Dr Sarah Barthelemy

HOSPITAL NAME

Aspen Animal Hospital

REFERRING VET

Dr Ross

INVOICE

23085

DATE

12/01/2025

Intact borderline thickened descending colon to colorectal wall was present. The colon was non-distended containing semi-formed/ soft fecal matter.

Pancreas

The pancreas was normal in size and contour with isoechoic to heterogeneous parenchyma compared to adjacent omentum. No signs of active inflammation or neoplasia.

Free Abdomen

No evidence of peritoneal effusion was present.

Intermittent indistinct mildly prominent to enlarged mesenteric lymph nodes were present. The lymph nodes were essentially isoechoic to adjacent omentum without evidence of peripheral inflammation and maintaining a normal width: length ratio (<0.5).

ULTRASONOGRAPHIC FINDINGS

Primary

- Previously noted mildly progressive splenic mass
- Mild heterogeneous liver with intraparenchymal nodule-lipogranuloma or nodular hyperplasia favored, potential for metastasis or early low grade primary hepatic neoplasia not excluded
- Static mild gallbladder debris (non-mucocele)
- Static chronic renal changes exhibiting mild pyelectasia

Secondary

- Pancreatic remodeling
- Subnormal left adrenal gland with mildly enlarged non-homogenous cranial right adrenal gland
- Intact mildly thickened ileocolic and descending colon wall with semi-formed/ soft fecal matter

INTERPRETATION OF THE FINDINGS & FURTHER RECOMMENDATIONS

The splenic mass is still non-specific although higher concern for neoplastic process, i.e. sarcoma warranted given evidence of mild progression compared to the previous study. Serial sonographic monitoring of the splenic mass as well as intermittent three view chest radiographs recommended assuming surgery is not an option. Correlation with recheck lab work and UA with reassessment of liver and renal parameters is recommended. Adrenal screening could be considered if clinical signs consistent with adrenal disease are present as well as monitoring of systemic BP for evidence of hypertension. Monitoring for gastrointestinal signs is recommended.



PATIENT

Buddy Dhillon

SPECIES

Canine

BREED

Goldendoodle

SEX

MN

AGE

16yr

WEIGHT

16kg

INTERPRETED BY

R. McKenzie Daniel,
DVM, DABVP
(Canine and Feline)

IMAGING PERFORMED BY

Dr Sarah Barthelemy

HOSPITAL NAME

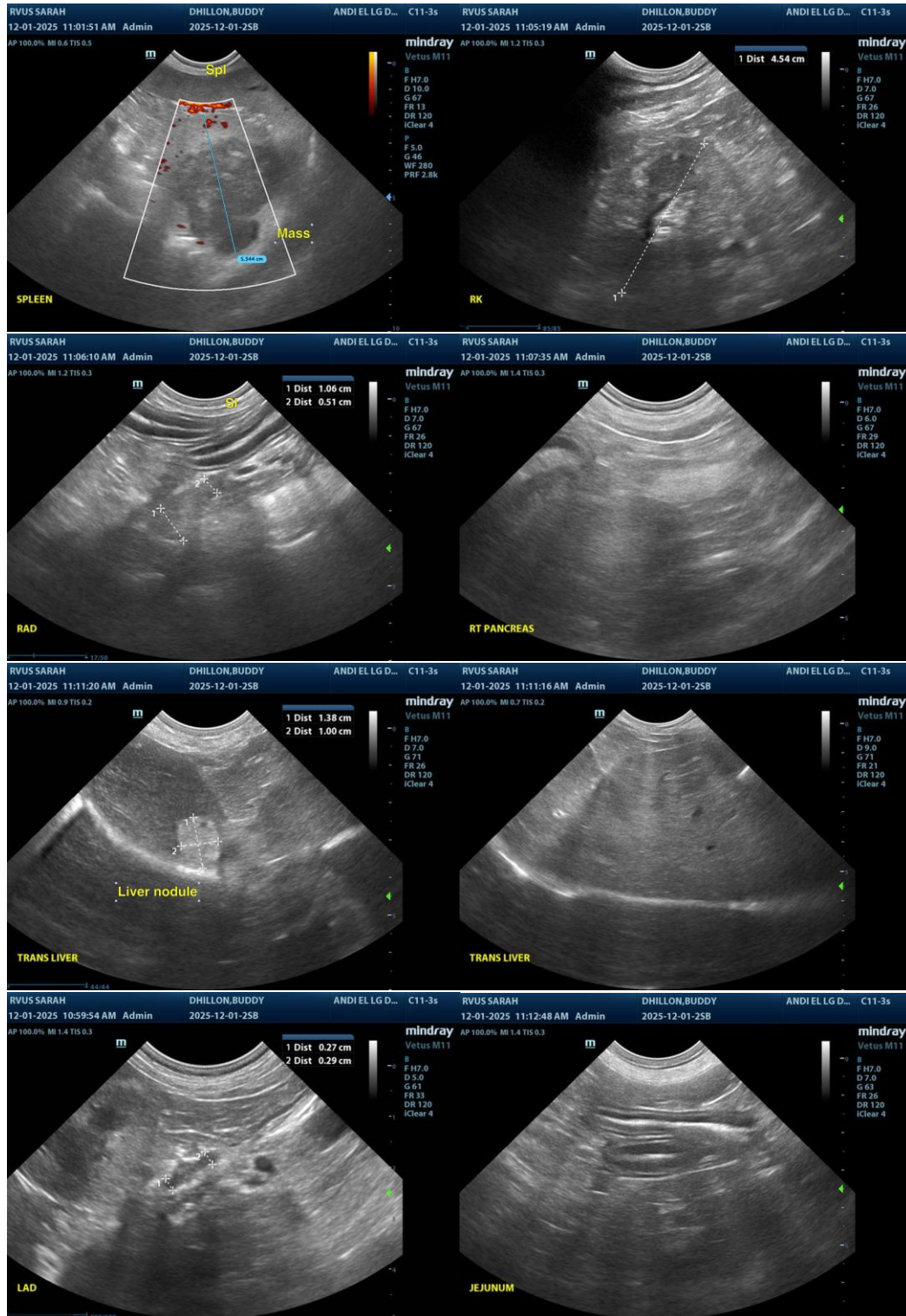
Aspen Animal Hospital

REFERRING VET

Dr Ross

INVOICE
23085

DATE
12/01/2025





PATIENT

Buddy Dhillon

SPECIES

Canine

BREED

Goldendoodle

SEX

MN

AGE

16yr

WEIGHT

16kg

INTERPRETED BY

R. McKenzie Daniel,
DVM, DABVP
(Canine and Feline)

IMAGING PERFORMED BY

Dr Sarah Barthelemy

HOSPITAL NAME

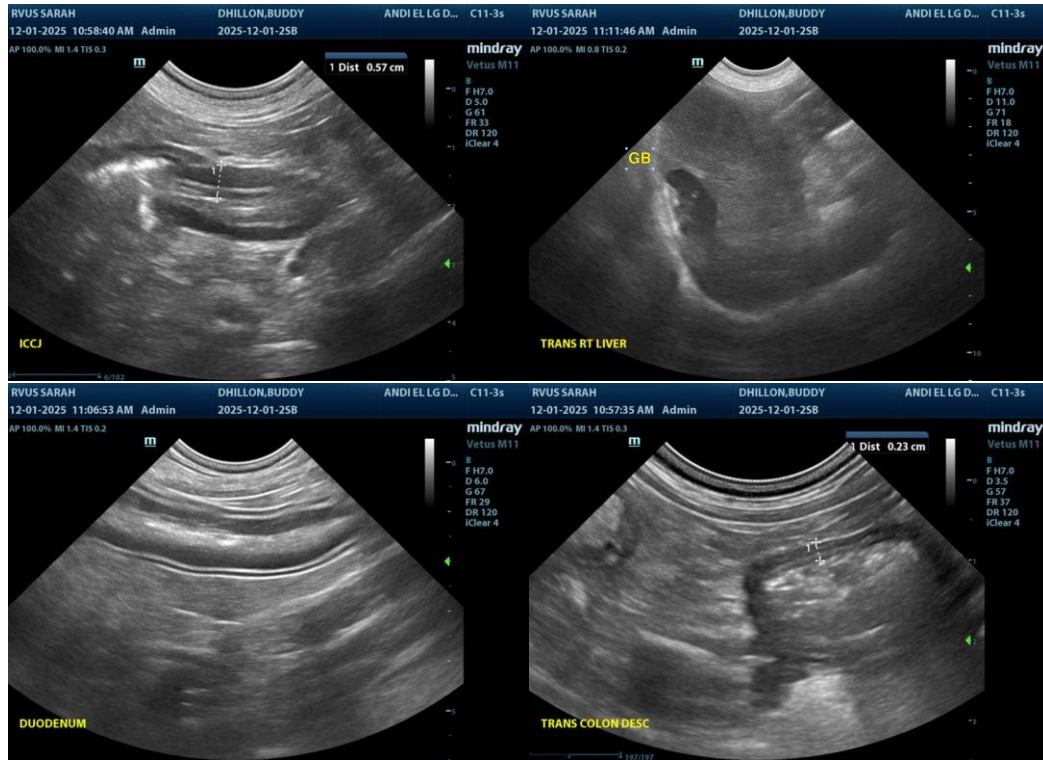
Aspen Animal Hospital

REFERRING VET

Dr Ross

INVOICE
23085

DATE
12/01/2025



The information and recommendations provided are based on the images presented by the referring veterinarian/sonographer. No evaluation can be communicated regarding pathology that was not visible in the image/video clips provided.

Thank you for this referral. If the clinical or image interpretation does not parallel your findings or if I can be of any further assistance, please contact me.

R. McKenzie Daniel, DVM, DABVP (Canine/Feline Practice)
info@sonopath.com